

A Novel Surgical Approach to Impacted Mandibular Third Molars to Reduce the Risk of Paresthesia: A Case Series

Luca Landi, DDS, CAGS,* Paolo Francesco Manicone, DDS,†
Stefano Piccinelli, DDS,‡ Alessandro Raia, DDS,§ and
Roberto Raia, DDS||

Purpose: Extraction of impacted mandibular third molars (M3s) may cause temporary or permanent neurosensory disturbances of the inferior alveolar nerve (IAN). Although the incidence of this complication is low, a great range of variability has been reported in the literature. Several methods to reduce or eliminate this complication have been proposed, such as orthodontic-assisted extraction, extraction of the second molar, or intentional odontectomy. The purpose of this series of cases is to present a novel approach for a riskless extraction of impacted mandibular M3s in contact with the IAN.

Materials and Methods: Nine consecutive patients (4 male and 5 female; mean age 24.9 years, range 18-43 years) required the extraction of 10 horizontally or mesioangular impacted mandibular M3s. In all cases the M3 was in contact with the IAN with a high risk of nerve injury. A staged approach was proposed and accepted by the patients. This approach consisted in the surgical removal of the mesial portion of the anatomic crown to create adequate space for mesial M3 migration. After the migration of the M3 had taken place, the extraction could then be accomplished in a second surgical session minimizing neurological risks.

Results: All M3s moved mesially within 6 months (mean 174.1 days, range 92-354 days) and could be successfully removed without any neurological consequences.

Conclusion: This technique may be considered as an alternative approach to the extraction of horizontally or mesioangular impacted M3s in proximity to the IAN.

© 2010 American Association of Oral and Maxillofacial Surgeons
J Oral Maxillofac Surg 68:969-974, 2010

Extraction of an impacted mandibular third molar (M3) has the potential risk of causing temporary or permanent neurologic disturbances of the inferior alveolar nerve (IAN).¹ The incidence of IAN injury

reported in the literature ranges from 1.3% to 5.3%.²⁻⁵ The risk of this complication depends mainly on the position of the impacted tooth in relation to the inferior alveolar canal before surgery.⁶ If there is close proximity between the IAN and the roots, the incidence may be as high as 19%.⁷ After a clear indication for extraction is defined, surgical removal of an impacted M3 with the roots in close contact with the IAN should attempt to minimize the risk of irreversible neurological complications. Several approaches in this regard have been proposed. Checchi et al^{8,9} introduced orthodontic-assisted extraction of impacted M3s, which has also been adopted by others.^{10,11} A partial intentional odontectomy has also been presented in the literature as a way to reduce neurological complications.^{7,12,13} The objective of this article is to present a novel approach to the surgical extraction of mandibular impacted M3 when there is a high risk of neurological damage to the IAN.

*Assistant Professor, Department of Prosthodontics, Catholic University of Sacred Heart, Rome, Italy.

†PhD Resident, Department of Orthodontics, Catholic University of Sacred Heart, Rome, Italy.

‡Assistant Professor, Department of Prosthodontics, Catholic University of Sacred Heart, Rome, Italy.

§PhD Resident, Department of Orthodontics, Catholic University of Sacred Heart, and Private Practice, Studio di Odontoiatria Ricostruttiva, Rome, Italy.

||Private Practice, Studio di Odontoiatria Ricostruttiva, Rome, Italy.

Address correspondence and reprint requests to Dr Landi: Via Della Balduina 114, 00136 Roma, Italy; e-mail: studio.ric@tin.it

© 2010 American Association of Oral and Maxillofacial Surgeons

0278-2391/10/6805-0004\$36.00/0

doi:10.1016/j.joms.2009.09.097

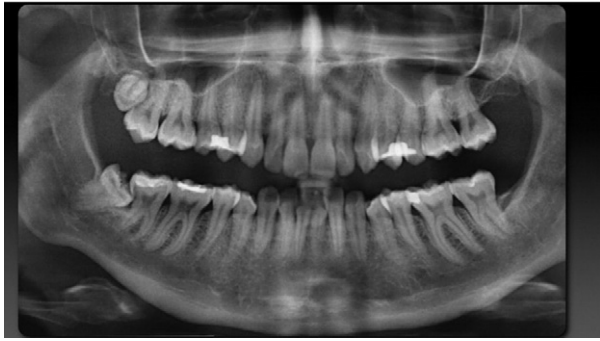

FIGURE 1. Initial panorex of a 41-year-old female patient. The right mandibular third molar is mesially impacted with the roots superimposed to the alveolar canal. At the distal aspect of the second molar, a caries lesion is detectable.

Landi et al. Surgical Approach to Impacted Mandibular Third Molars. J Oral Maxillofac Surg 2010.

Materials and Methods

Nine consecutive patients (5 female and 4 male, mean age 24.9 years, range 18-43 years) were referred to our clinic for extraction of impacted mandibular M3s. One patient presented with bilateral impaction, and 10 consecutive impacted M3s were treated. The reasons for extraction were orthodontic treatment (5 cases) or caries of the second molar (4 cases). Seven M3s were horizontally impacted, and 3 were mesio-angulated. In all cases, panorex showed the root apex

in contact with the IAN (Fig 1). A computed tomography scan was used to confirm the close proximity of the root apex and the alveolar canal (Fig 2). As a result, all 10 extractions were at high risk of postoperative neurologic disturbance. Various treatment options were discussed with patients, including extraction of the second molar (M2). For those patients who had an orthodontic indication, a no-treatment option was also discussed. Orthodontic-assisted extraction was discarded either because it was judged too demanding for the horizontal position of the M3 or because it was rejected by the patient. A staged surgical extraction to reduce nerve damage risk was proposed to all patients. The goal of this technique was to allow spontaneous mesial migration of the impacted M3 by sectioning the portion of the M3 crown in contact with the distal aspect of the M2. All patients accepted and signed the informed consent forms.

Technique Description

This technique has been also described in another article.¹⁴ A periapical radiograph of the area is taken before surgery and stored for follow-up comparison. The surgery is approached as it would be for extraction of an impacted M3. Block anesthesia is administered with local infiltration of the buccal nerve. A

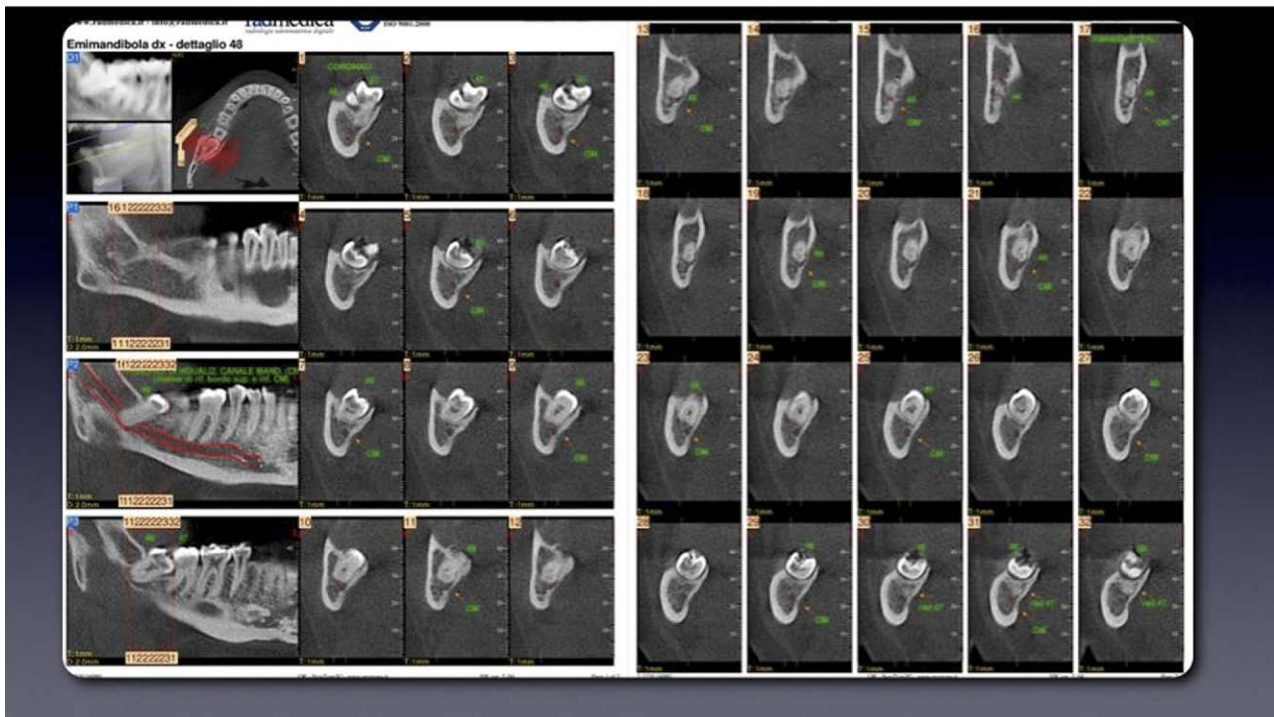


FIGURE 2. Computed tomography scan of the right third molar area. The close proximity of the roots of the right mandibular third molar and the inferior alveolar nerve bundle is clearly visible. Tooth extraction would result in a high risk of nerve injury.

Landi et al. Surgical Approach to Impacted Mandibular Third Molars. J Oral Maxillofac Surg 2010.

hockey-stick incision is outlined, and a full thickness flap is raised. After osteotomy, using a carbide and diamond bur, is completed, access is gained to the impacted tooth; then, using a fissure bur, the mesial portion of the anatomic crown is sectioned and removed. Care should be taken to avoid pulp exposure at this stage (Fig 3). The distance between the distal aspect of M2 and the mesial aspect of the sectioned M3 is measured and recorded for migration evaluation. Postoperative management includes pain medications (ibuprofen 400 mg, 3 times a day) and mouth rinses with chlorhexidine (0.2% twice a day for 10 days). After removal of the sutures, patients are instructed to clean the area. A monthly exam is scheduled for the first 3 months. At 3 months, a new periapical x-ray is taken to assess the degree of migration of the M3 (Fig 4). If indicated, a new panorex is also prescribed to assess the relationship between the roots and the IAN. After migration of the M3 is judged adequate for a risk-free extraction, the surgical removal of the impacted tooth may be scheduled.

Results

In all cases, healing was uneventful. Three to 4 months after the surgery, all M3s moved forward and reached the distal aspect of the second molars. In 8 cases, the periapical radiograph (6 cases) or panorex (2 cases) demonstrated clearance between the roots and the IAN so that a risk-free extraction could be scheduled. In 2 cases, the degree of migration was judged inadequate to extract the teeth safely. Therefore, a second surgical section was required to gain further space for mesial migration. Under local anesthesia, a mucoperiosteal flap was raised without vertical releasing incision, and an additional section of the M3 was accomplished (Fig 5). In both cases, the pulp chamber was exposed, and a pulpotomy was carried out. A temporary filling material (Coltosol;

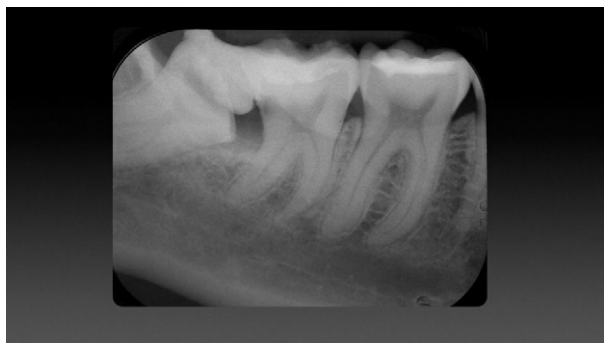

FIGURE 3. Postoperative radiograph after odontectomy. A space distal to the second molar is created to allow migration of the impacted tooth.

Landi et al. Surgical Approach to Impacted Mandibular Third Molars. J Oral Maxillofac Surg 2010.

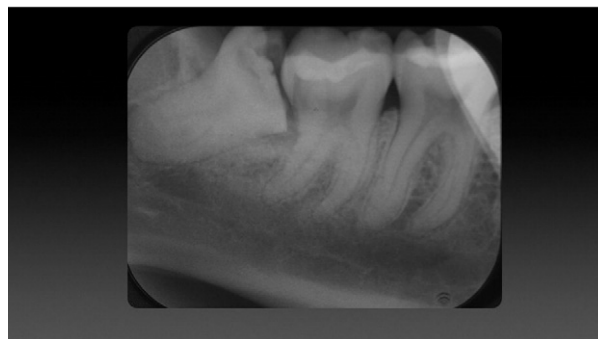


FIGURE 4. Seventy-six days after odontectomy: the M3 moved mesially reaching the distal aspect of the second molar. No further migration may be expected. No clearance between the inferior alveolar nerve and the roots is visible, and a second section is required.

Landi et al. Surgical Approach to Impacted Mandibular Third Molars. J Oral Maxillofac Surg 2010.

Coltene Whaledent, Langenau, Germany) was used to seal the pulp chamber access. Three months later, a new periapical radiograph of the area confirmed the further mesial shifting of both teeth. This time, the position of the M3 was judged adequate for a safe extraction (Fig 6). Excluding the first case of the series for which 8 months passed before taking a new radiograph and another case in which the patient returned to the clinic after 1 year, the extraction was carried out within 6 months (mean 131.9 days; range, 92-183) from the first surgery. All M3 extractions (including those requiring only 1 sectioning) were carried out with minimal surgical trauma because no osteotomy was required and the teeth were highly mobile because of the eruption process. No postoperative sequelae have been reported, and patients reported minimal discomfort.

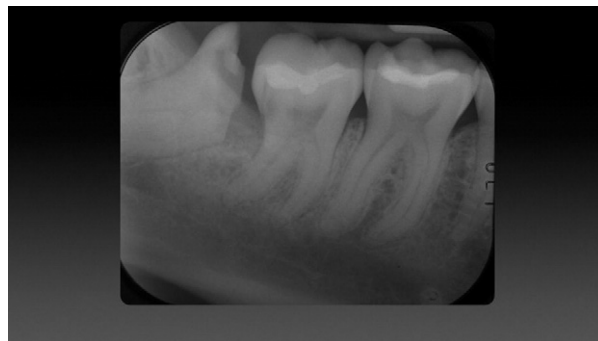

FIGURE 5. Postoperative radiograph after second section of the right mandibular third molar. A pulpotomy has been carried out. More space is created distal to the right mandibular second molar to allow further migration.

Landi et al. Surgical Approach to Impacted Mandibular Third Molars. J Oral Maxillofac Surg 2010.

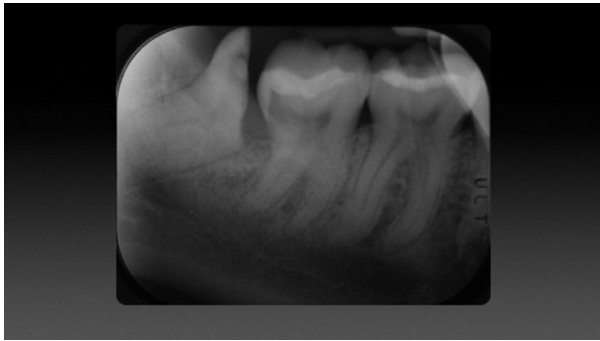


FIGURE 6. Periapical x-rays taken 76 days after the second surgery. The third molar shifted further mesially. Here the position is adequate for a risk-free extraction.

Landi et al. Surgical Approach to Impacted Mandibular Third Molars. J Oral Maxillofac Surg 2010.

Discussion

Extraction of an impacted M3 may result in a temporary or permanent injury of the IAN. Although the incidence of such a complication is relatively low, its frequency increases as the roots of the impacted tooth move closer to the IAN.⁶ To reduce the neurological risks, several strategies may be used. Checchi et al⁸ introduced the use of an orthodontic appliance to move the impacted M3 away from the IAN. Using the same technique, Bonetti et al⁹ were able to extract a deeply vertically impacted M3 without any neurological consequences. Five months after active orthodontic therapy, the M3 reached a safe position. Three months of stabilization allowed mineralization of the newly formed tissue before extraction to improve the periodontal attachment level at the distal aspect of the M2, which was severely affected by the presence of the impacted tooth. The authors mentioned that this technique, although effective in reducing the risk of paresthesia, is time-consuming and expensive and may not be well tolerated by the patient. The orthodontic device is applied in a difficult area of the mouth and may cause compression and ulceration of the neighboring tissues with a degree of discomfort. To overcome the risk of IAN injury, intentional odontectomy has also been proposed.^{7,12,13} Renton et al⁷ reported the results from a randomized controlled clinical trial comparing the incidence of IAN injury because of coronectomy to the extraction of mandibular impacted M3 with the roots in contact with the nerve bundle. The incidence of nerve injury was 19% in the extraction group and 0% in the coronectomy group. Of 58 coronectomies, no roots required reoperation or removal during the 2-years' follow-up. It is noteworthy that of the 94 molars assigned to the coronectomy group, 36 had to be removed during surgery because of accidental root dislodgement. In those cases, the incidence of IAN

injury was 8%. No case of IAN injury was reported by Pogrel et al¹² in 41 patients requiring the extraction of impacted M3s in proximity to the IAN. Over 6 months after the coronectomy, only 1 sectioned molar required extraction due to impaired healing, and another molar migrated to the occlusal plane and was extracted. A slightly higher incidence (3/52) of sectioned molar requiring extraction over time was reported by O'Riordan,¹³ confirming a relatively low rate of complications compared with the relatively high incidence of IAN injury. The novel approach presented here aims to provide adequate space distal to the second molar to allow spontaneous M3 eruption to move the roots away from the neurovascular bundle. Evidence suggests that in young adults, 26% to 35% of unerupted mandibular M3 may change position over time and reach the occlusal plane.^{15,16} Bayram et al¹⁷ showed that extraction of the first molar for orthodontic reasons in young patients increases the eruption space for M3, reducing impaction. Furthermore, 30% of the impacted M3 that underwent coronectomy showed mesial migration over a 6-month period.¹² This residual erupting activity of impacted M3 seems to be influenced by the pattern of impaction because only 3% of horizontally or mesio-angulated impacted M3, with an angle of impaction $>35^\circ$, may spontaneously erupt, compared with more than 30% of vertically positioned M3.¹⁶ Therefore, it may be speculated that if space is provided mesial to the M3, a spontaneous migration of the tooth may be possible. This novel technique aims to exploit this potential eruption by providing space distal to the second molar by removing a portion of the M3 crown. The amount of sectioning should take into account several factors: 1) tooth position and angulations (Fig 7), 2) degree of mesial shift desired to move the roots away from the nerve; and 3) pulp

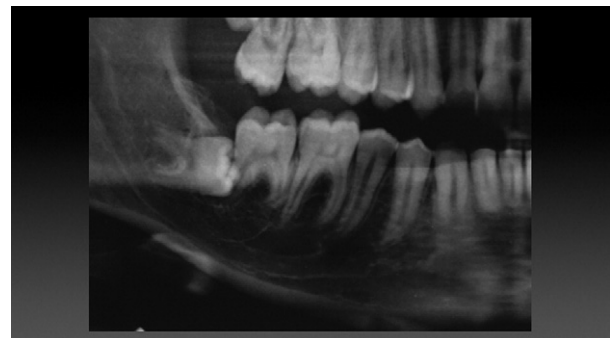


FIGURE 7. Partial panorex radiograph of a 19-year-old male patient at the initial consultation. The right mandibular third molar is horizontally impacted, and the patient complained with pain and discomfort at the area. The apex of the mesial root is in the proximity of the alveolar canal.

Landi et al. Surgical Approach to Impacted Mandibular Third Molars. J Oral Maxillofac Surg 2010.

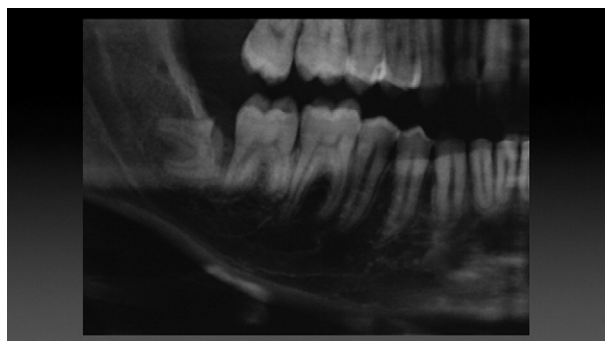


FIGURE 8. Partial panorex taken 3 months after the odontectomy before tooth extraction. The residual third molar moved mesially so that there is clearance between the apex of the mesial root and the inferior alveolar nerve. A risk-free extraction may be accomplished.

Landi et al. Surgical Approach to Impacted Mandibular Third Molars. J Oral Maxillofac Surg 2010.

chamber anatomy. Although a generous sectioning is desirable (Fig 8), every effort should be made, at least during the first odontectomy, not to interfere with tooth vitality. In case of accidental pulp exposure, a pulpotomy may be performed to minimize the risk of postoperative pain and discomfort. This approach could be selected according to the following criteria: 1) radiographic proximity of the M3 roots with the IAN confirmed on a computed tomography scan; 2) horizontal or mesioinclined M3 impaction; 3) contact of the M3 crown with the distal aspect of the M2; 4) an established pathological process is detectable in the area of impaction (pericoronitis, caries, or deep periodontal defect), indicating the need of M3 removal; 5) orthodontic-assisted extraction is judged complex to apply or is not accepted by the patient; 6) preferable (but not exclusive) young patient age because higher residual eruption activity may be expected and age is considered a risk factor for M3 extraction complications.¹⁷ Our approach may also reduce chair time and procedural costs compared with the orthodontic-assisted technique, while improving patient comfort, because no intraoral appliances are required. Another possible advantage may be in cases of ankylosis, in which orthodontic therapy would fail to achieve any tooth movement and might cause undesired movement of the anchoring teeth. With our approach, if no movement is detected, the sectioned M3 may be left in place as for an intentional odontectomy,^{7,12,13} provided no signs or symptoms of pathology occur. Of note is that in the cases reported by Renton et al,⁷ Pogrel et al,¹² and O'Riordan,¹³ only 4 of 160 (2.5%) M3s that underwent coronectomy had to be extracted during the follow-up because of pain or infection. A potential drawback of this approach is the double surgical procedures. However, the technique compares well with the orthodontic-assisted extraction for which 2 surgical procedures are often

considered. Clinicians and patients should be also aware of the possibility that a further sectioning may be carried out when a greater migration is required. This would lead to a third surgical, albeit minor, procedure. In our limited experience, this occurred twice in the first 3 cases, but no further sectioning was required in the subsequent 7 cases. There may be several explanations for this: the existence of a physiologic learning curve to anticipate the space required for adequate tooth migration, attempts to preserve the pulp integrity as much as possible, and the anatomic determinants of those specific cases (tooth position, tooth anatomy, and pulp chamber architecture). It is worth noting that the second sectioning was a minimally invasive procedure that may be comparable, in terms of length and intraoperative discomfort, to an endodontic or a restorative procedure. Another potential complication that should be considered is postoperative tooth hypersensitivity induced by the odontectomy. This complication took place twice and was resolved in both cases within 5 days. No dry socket, trismus, or impaired healing was recorded in all treated cases. This series of cases showed that intentional odontectomy of horizontally or mesioangulated impacted M3s with the roots close to the IAN may be followed by spontaneous mesial migration of the sectioned tooth over time. This novel approach may be promising to reduce the risk of nerve injury during impacted M3 extraction. Further investigations on larger population may be warranted to evaluate its efficacy in the long term.

References

1. Libersa P, Savignat M, Tonnel A: Neurosensory disturbances of the inferior alveolar nerve: A retrospective study of complaints in a 10-year period. *J Oral Maxillofac Surg* 65:1486, 2007
2. Bataineh AB: Sensory nerve impairment following mandibular third molar surgery. *J Oral Maxillofac Surg* 59:1012, 2001
3. Kipp DP, Goldstein BH, Weiss WW: Dysesthesia after mandibular third molar surgery: A retrospective study and analysis of 1,377 surgical procedures. *J Am Dent Assoc* 100:185, 1980
4. Goldberg MH, Nemarich AN, Marco WP: Complications after mandibular third molar surgery: A statistical analysis of 500 consecutive procedures in private practice. *J Am Dent Assoc* 111:277, 1985
5. Smith AC, Barry SE, Chiong AY, et al: Inferior alveolar nerve damage following removal of mandibular third molar teeth: A prospective study using panoramic radiography. *Aust Dent J* 42:149, 1997
6. Bui CH, Seldin EB, Dodson DB: Types, frequencies and risk factors for complications after third molar extraction. *J Oral Maxillofac Surg* 61:1379, 2003
7. Renton T, Hankins M, Sproate C, et al: A randomized controlled clinical trial to compare the incidence of injury to the inferior alveolar nerve as a result of coronectomy and removal of mandibular third molar. *Br J Oral Maxillofac Surg* 43:7, 2005
8. Checchi L, Bonetti GA, Pelliccioni GA: Removing of high-risk impacted mandibular third molar. A surgical orthodontic approach. *J Am Dent Assoc* 127:1214, 1996
9. Bonetti GA, Bendandi M, Laino L, et al: Orthodontic extraction: Riskless extraction of impacted lower third molars close to the mandibular canal. *J Oral Maxillofac Surg* 65:2580, 2007

10. Hirsch A, Shteiman S, Boyan BD, et al: Use of orthodontic treatment as an aid to third molar extraction: A method for prevention of mandibular nerve injury and improved periodontal status. *J Periodontol* 74:887, 2003
11. Pogrel MA, Lee JS, Muff DF: Coronectomy: A technique to protect the inferior alveolar nerve. *J Oral Maxillofac Surg* 62:1447, 2004
12. O'Riordan BC: Coronectomy (intentional partial odontectomy of a lower third molar). *Oral Surg Oral Med Oral Pathol Oral Radiol Endod* 98:274, 2004
13. Landi L, Manicone PF, Piccinelli S, et al: Spontaneous migration of horizontally impacted third molars after surgical odontectomy: A case report. *J Oral Maxillofac Surg* 68:442, 2010
14. Phillips C, Norman J, Jaskolka M, et al: Changes over time in position and periodontal probing status of retained third molars. *J Oral Maxillofac Surg* 65:2011, 2007
15. Nance P, White R Jr, Offenbacher S, et al: Change in third molar angulation and position in young adults and follow-up periodontal pathology. *J Oral Maxillofac Surg* 64:424, 2006
16. Bayram M, Ozer M, Arici S: Effects of first molar extraction on third molar angulation and eruption space. *Oral Surg Oral Med Oral Pathol Radiol Endod* 107:e14-e20, 2009
17. Chuang S-K, Perrot DH, Susarla SM, et al: Age as a risk factor for third molar surgery complications. *J Oral Maxillofac Surg* 65:1658, 2007